PART 11 | Abdominal

CHAPTER

70 The spleen

Learning objectives

To understand:

- The function of the spleen
- The common pathologies involving the spleen
- The principles and potential complications of splenectomy
- The potential advantages of laparoscopic splenectomy
- The benefits of splenic conservation
- The importance of prophylaxis against infection following splenectomy

EMBRYOLOGY, ANATOMY AND PHYSIOLOGY

Embryology

Fetal splenic tissue develops from condensations of mesoderm in the dorsal mesogastrium. This peritoneal fold attaches the dorsal body wall to the fusiform swelling in the foregut that develops into the stomach. This condensation divides the mesogastrium into two parts, one between the fetal splenic tissue and the stomach to form the gastrosplenic ligament and the other between it and the left kidney to form the lienorenal ligament.

Anatomy

The weight of the normal adult spleen is 75–250 g and it measures up to 10 × 7 × 3 cm. It lies in the left hypochondrium between the gastric fundus and the left hemidiaphragm, with its long axis lying along the 10th rib. The spleen is connected to the stomach and kidney by a double fold of peritoneum that originates from the stomach as a part of the greater omentum. The gastrosplenic (gastrolienal) ligament is anterior to the splenic hilum and connects the spleen to the greater curvature of the stomach. The splenorenal (lienorenal) ligament lies posterior to the splenic hilum and connects the hilum of the spleen to the left kidney. The splenic vessels and the tail of the pancreas lie within this ligament (***Figure 70.1***). The hilum of the spleen sits in the angle between the stomach and the kidney and is in contact with the tail of the pancreas. The concave visceral surface lies in contact with these structures, and the lower pole extends no further than the midaxillary line. There is a notch on the inferolateral border, and this may be palpated only when the spleen is enlarged. The tortuous splenic artery arises from the coeliac axis and runs along the upper border of the body and tail of the pancreas, to which it gives small branches. The short gastric and left gastroepiploic branches pass between the layers of the gastrosplenic ligament. These arteries are divided whenever the greater curvature of the stomach has to be excised. The main splenic artery generally divides into superior and inferior branches, which, in turn, subdivide into several segmental branches. The splenic vein is formed from several tributaries that drain the hilum and runs behind the pancreas, receiving several small tributaries from the pancreas before joining the superior mesenteric vein at the neck of the pancreas to form the portal vein (***Figure 70.2***).

The splenic pulp is invested by an external serous and internal fibroelastic coat, which is reflected inwards at the hilum onto the vessels to form vascular sheaths. The lymphatic drainage comprises efferent vessels in the white pulp that run with the arterioles and emerge from nodes at the hilum. These nodes and lymphatics drain via retropancreatic nodes to the coeliac nodes.

Physiology

The splenic parenchyma consists of white and red pulp that is surrounded by serosa and a collagenous capsule with smooth muscle fibres. These penetrate the parenchyma as trabeculae of dense connective tissue fibres rich in collagen and elastic tissue. These, with the reticular framework, support the cells of the spleen and surround the vessels in the splenic pulp. The white pulp comprises a central trabecular artery surrounded by nodules with germinal centres and periarterial lymphatic sheaths that provide a framework filled with lymphocytes and macrophages. Arteries from the central artery and the peripheral 'penicillar' arteries pass into the marginal zone that lies at the edge of the white pulp. Plasma-rich blood that has passed through the central lymphatic nodules is filtered as it passes through the sinuses within the marginal zone, and particles are phagocytosed.

Immunoglobulins produced in the lymphatic nodules enter the circulation through the sinuses in the marginal zone,

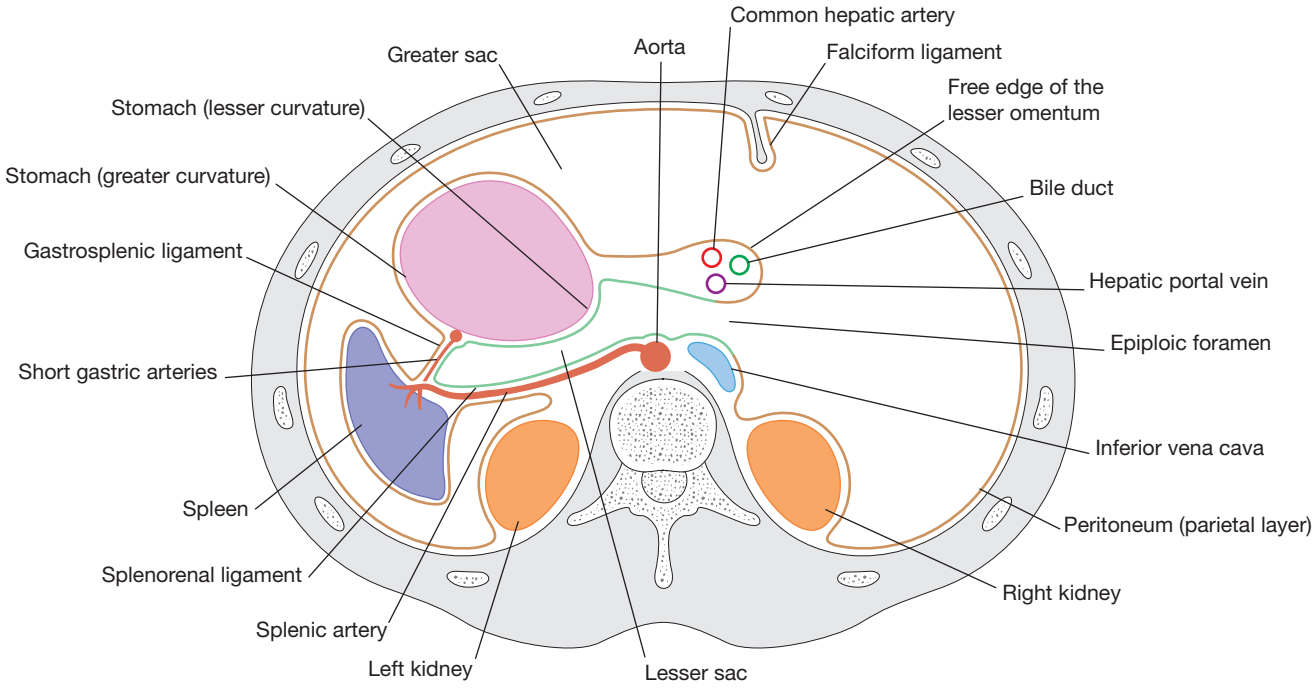

Figure 70.1 Transverse section (craniocaudal view) showing the important ligaments of the spleen containing the blood vessels (courtesy of Dr Tusharindra Lal, Chennai, India).

beyond which lies the red pulp, which consists of cords and sinuses. Cell-concentrated blood passes in the trabecular artery through the centre of the white pulp to the red pulp cords. Red cells must elongate and become thinner to pass from the cords to the sinuses, a process that removes abnormally shaped cells from the circulation (***Figure 70.3***). As 90% of the blood passing through the spleen moves through an open circulation in which blood flows from arteries to cords, and thence sinuses, splenic pulp pressure reflects the pressure throughout the portal system. The remaining 10% of the blood flow through the spleen bypasses the cords and sinuses by direct arteriovenous communications. The overall flow rate of blood is about 300 mL/min.

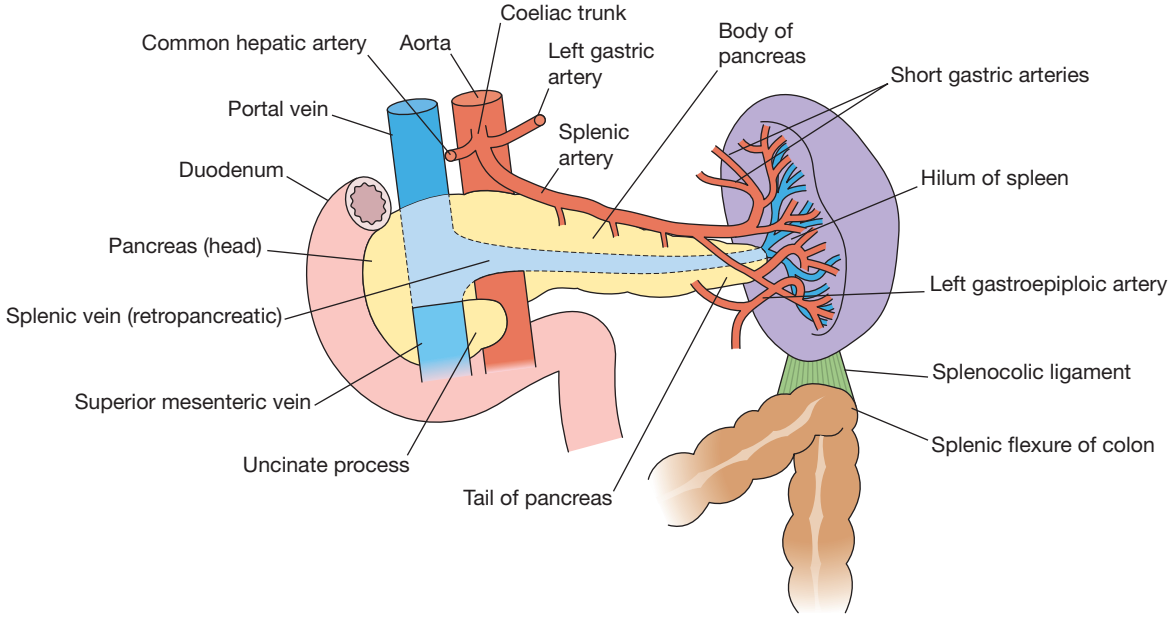

Figure 70.2 Schematic representation showing relations at the hilum of the spleen with the blood supply and venous drainage. Note the avascular splenocolic ligament that needs to be divided carefully to free the inferior pole of the spleen from the splenic flexure (courtesy of Dr Tusharindra Lal, Chennai, India).

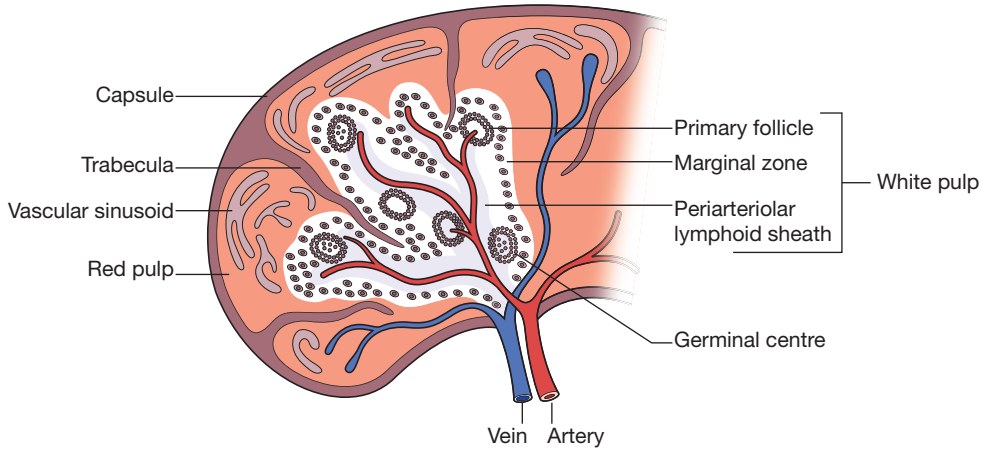

Figure 70.3 Functional anatomy of the spleen. Blood from a central trabecular artery passes through the white pulp into the surrounding red pulp and hence to the vascular cords and sinuses that drain into the trabecular vein.

FUNCTIONS OF THE SPLEEN

Although the spleen was previously thought to be dispensable, it is now recognised that an incidental splenectomy during the course of another operative procedure increases the risk of complications and death. The surgeon should therefore normally endeavour to preserve the spleen to maintain the following functions.

- **Immune function**. The spleen contains 70.5% and 10–15% of the body's total T and B lymphocyte population, respectively. It processes foreign antigens and is the major site of specific immunoglobulin (Ig) M production. The non-specific opsonins, properdin and tuftsin, are synthesised. These antibodies are of B- and T-cell origin and bind to the specific receptors on the surface of macrophages and leukocytes, stimulating their phagocytic, bactericidal and tumoricidal activity. Loss of this function necessitates vaccination against capsulated microorganisms such as pneumococci in splenectomised patients.
- **Filter function**. Macrophages in the reticulum capture cellular and non-cellular material from the blood and plasma. This will include the removal of effete platelets and red blood cells. This process takes place in the sinuses and the splenic cords by the action of the endothelial macrophages. Iron is removed from the degraded haemoglobin during red cell breakdown and is returned to plasma. Removed non-cellular material may include bacteria and, in particular, pneumococci. This occurs in the red pulp of the spleen and needs red cells with the capability to change shape and traverse through the sinusoids. As the deformability is reduced in spherocytosis, the cells get removed in the spleen. Splenectomy is recommended in such patients to maintain the haemoglobin concentration.
- **Pitting**. Distorted red cells in sickle cell disease result in slowing of circulation with multiple splenic infarcts, leading to loss of splenic function – autosplenectomy. This leads to the appearance of circulating red cells with Howell–Jolly and Heinz bodies, which represent nuclear remnants and precipitated haemoglobin or globin subunits, respectively, and appear as target cells on a smear. These particulate inclusions within the red cells are removed, and the repaired red cells are returned to the circulation in the process of pitting.
- **Reservoir function**. This function in humans is less marked than in other species, but the spleen does contain approximately 8% of the red cell mass. An enlarged spleen may contain a much larger proportion of the blood volume. Massive splenic enlargement will be associated with a larger proportion of blood volume in the spleen, leading to pancytopenia, which can be corrected by splenectomy.
- **Cytopoiesis**. From the fourth month of intrauterine life, some degree of haemopoiesis occurs in the fetal spleen. Stimulation of the white pulp may occur following antigenic challenge, resulting in the proliferation of T and B cells and macrophages. This may also occur in myeloproliferative disorders, thalassaemias and chronic haemolytic anaemias.

Summary box 70.1

Functions of the spleen

- Immune
- Filter function
- Pitting
- Reservoir
- Cytopoiesis

William Henry Howell, 1860–1945, Professor of Physiology, Johns Hopkins University, Baltimore, MD, USA.
Justin Marie Jules Jolly, 1870–1953, Professor of Histopathology, Collège de France, Paris, France.
Robert Heinz, 1865–1962, Professor of Pharmacology and Toxicology, Erlangen, Germany.

INVESTIGATION OF THE SPLEEN

Conditions that result in splenomegaly can be diagnosed on the basis of the history and examination and laboratory examination. In haemolytic anaemia, a full blood count, reticulocyte count and tests for haemolysis will determine the cause of the anaemia. Splenomegaly associated with portal hypertension caused by cirrhosis is diagnosed on history, physical signs of liver dysfunction including ascites, abnormal tests of liver function, often anaemia, leukopenia and thrombocytopenia, as well as endoscopic evidence of oesophageal varices. Non-cirrhotic portal fibrosis, a condition common in tropical countries, is associated with massive splenomegaly and pancytopenia without stigmata of liver dysfunction. Sinistral or segmental portal hypertension may result from isolated occlusion of the splenic vein by thrombosis, pancreatic inflammation or tumour infiltration. As many conditions that cause splenomegaly are associated with lymphadenopathy, investigation should be directed at those disease processes known to be associated with both physical signs. Lymph node biopsy may be required.

Radiological imaging

Plain radiology is rarely used in investigation, but the incidental finding of calcification of the splenic artery or spleen may raise the possible diagnosis of a splenic artery aneurysm, an old infarct, a benign cyst or hydatid disease. Multiple areas of calcification may suggest splenic tuberculosis. Ultrasonography can determine the size and consistency of the spleen and whether a cyst is present. However, computed tomography (CT) with contrast enhancement is more commonly undertaken to better characterise the nature of the suspected splenic pathology and to exclude other intra-abdominal pathology. Magnetic resonance imaging (MRI) may be similarly useful, especially as T2-weighted images allow cystic lesions to be distinguished.

CONGENITAL ABNORMALITIES OF THE SPLEEN

Splenic agenesis is rare but is present in 5% of children with congenital heart disease. Polysplenia is a rare condition resulting from failure of splenic fusion.

Splenunculi are single or multiple accessory spleens that are found in approximately 10–30% of the population. They are located near the hilum of the spleen in 50% of cases and are related to the splenic vessels, or behind the tail of the pancreas in 30%. The remainder are located in the mesocolon, greater omentum or the splenic ligaments. Their significance lies in the fact that failure to identify and remove these at the time of splenectomy may give rise to persistent disease.

Hamartomas are rarely found in life and vary in size from 1 cm in diameter to masses large enough to produce an abdominal swelling. One form is mainly lymphoid and resembles the white pulp, whereas the other resembles the red pulp.

Non-parasitic **splenic cysts** are rare. Splenic cysts are classified as primary cysts (true) or pseudocysts (secondary) on the basis of the presence or absence of lining epithelium. True cysts form from embryonal rests and include dermoid and mesenchymal inclusion cysts (***Figure 70.4***). Rarely, the entire spleen may be replaced by a cystic mass (***Figure 70.5***). True cysts of the spleen are very rare and are frequently classified as cystic haemangiomas, cystic lymphangiomas and epidermoid and dermoid cysts. Splenectomy or partial splenectomy is usually considered for cysts larger than 5 cm in diameter. These should be differentiated from false or secondary cysts that may result from trauma and contain serous or haemorrhagic fluid. The walls of such degenerative cysts may be calcified and therefore resemble the radiological appearances of a hydatid cyst (***Figure 70.6***). The spleen is also a common site for pseudocyst development following a severe attack of pancreatitis (***Figure 70.7***). Pseudocysts can easily be diagnosed on scanning; intervention is normally required for symptomatic lesions that persist following a period of observation.

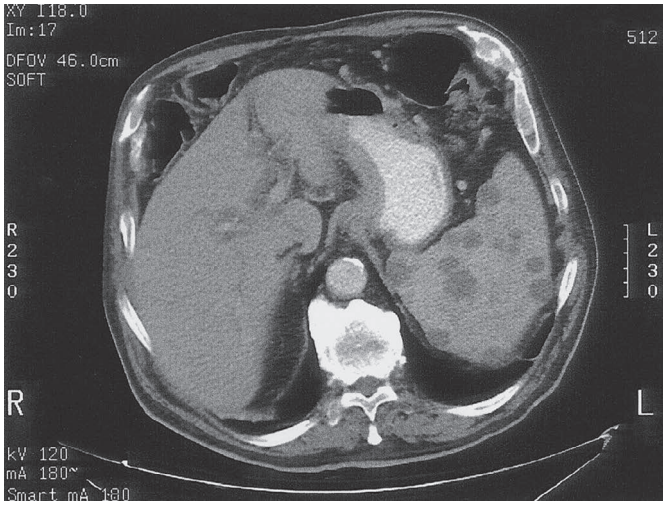

Figure 70.4 Computed tomography scan showing multiple low-density areas in the spleen consistent with multiple benign splenic cysts.

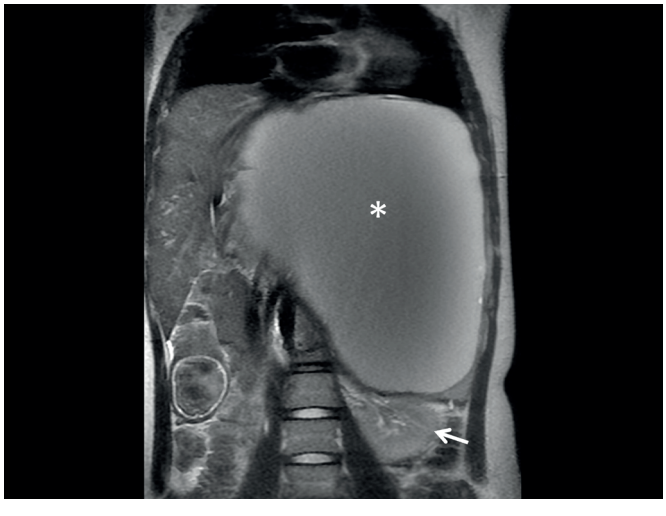

Figure 70.5 T2-weighted coronal magnetic resonance image showing a large, homogeneously hyperintense lesion (asterisk) in the region of the spleen displacing the left kidney inferiorly (arrow). Note that the normal splenic parenchyma is completely replaced by the cyst (courtesy of Dr Amit Kumar Sahu, New Delhi, India).

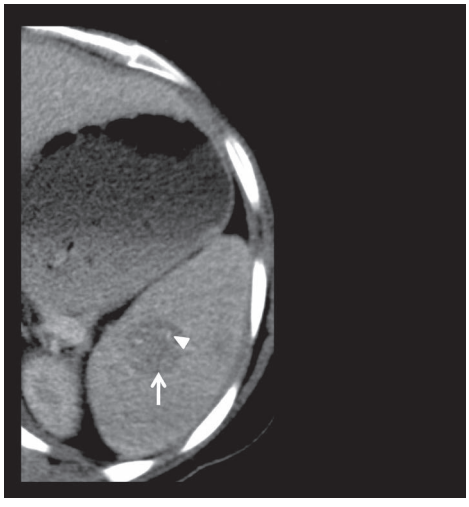

Figure 70.6 Axial contrast-enhanced computed tomography scan shows a well-defined hypodense lesion (arrow) in the spleen with mild internal calcification suggestive of splenic hydatid (arrowhead) (courtesy of Dr Amit Kumar Sahu, New Delhi, India).

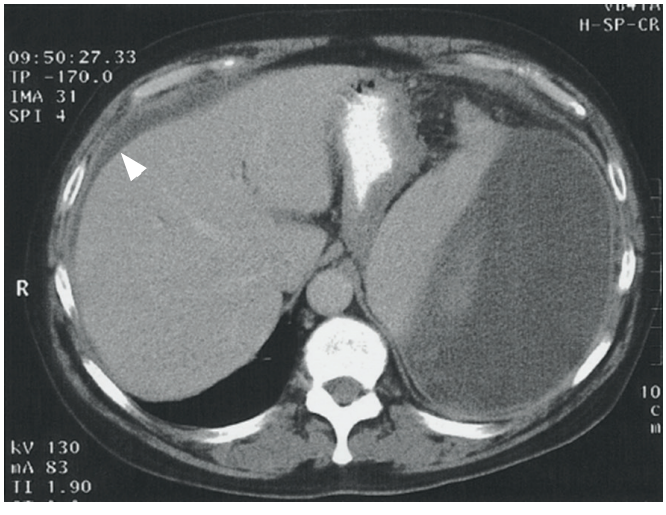

Figure 70.7 Computed tomography scan showing a large pseudocyst involving the spleen. There is displacement of the stomach medially and a trace of ascitic fluid (arrowhead) is present above the liver.

SPLENIC ARTERY ANEURYSM, INFARCT AND RUPTURE

Splenic artery aneurysm

Aneurysms involving the splenic artery are estimated to be identified at 0.04–1% of postmortem examinations. They are twice as common in women and are usually situated in the main arterial trunk. Although these are generally single, more than one aneurysm is found in one-quarter of cases. These may be a consequence of intra-abdominal sepsis and pancreatic necrosis, in particular. They are more likely to be associated with arteriosclerosis in elderly patients.

The aneurysm is symptomless unless it ruptures and is more likely to be detected on a plain abdominal radiograph or scan. It is unlikely to be palpable, although a bruit may be present. Rupture is unsuspected in the majority of cases and, as it will generally rupture into the peritoneal cavity, the symptoms mimic those of splenic rupture. Almost half the cases of rupture occur in patients younger than 45 years of age and one-quarter are in pregnant women, usually in the third trimester of pregnancy or at labour. Aneurysmal rupture carries a high mortality rate and this increases disproportionately in pregnant women, with almost inevitable fetal death.

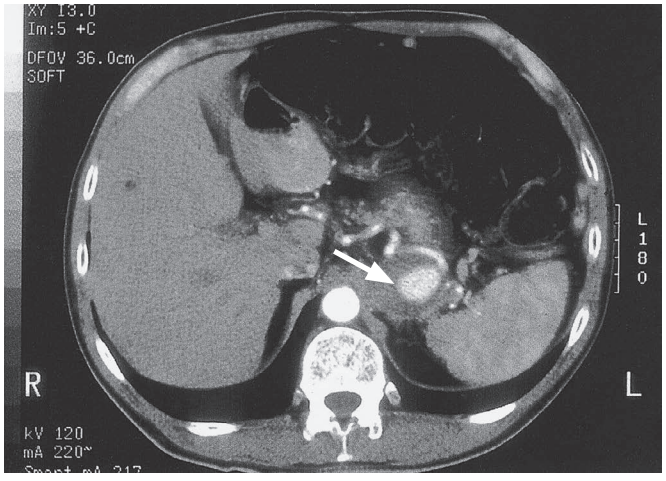

Figure 70.8 Computed tomography scan showing a pool of contrast in a pseudoaneurysm (arrow) situated in the tail of the pancreas adjacent to the spleen.

The treatment of choice previously consisted of splenectomy and removal of the diseased artery. Embolisation or endovascular stenting following selective splenic artery angiography can be considered and is now more commonly undertaken. In younger patients with an asymptomatic splenic artery aneurysm, surgery or interventional radiology is indicated, depending on local expertise, after CT scan, MRI or selective coeliac angiography has confirmed the diagnosis (***Figure 70.8***). In elderly patients with a calcified aneurysm, there is less risk of rupture and observation may be preferred.

Splenic infarction

This condition commonly occurs in patients with a massively enlarged spleen from myeloproliferative syndrome, portal hypertension or vascular occlusion produced by previous surgical intervention (such as spleen-preserving distal pancreatectomy), pancreatic disease, splenic vein thrombosis or sickle cell disease. The infarct may be asymptomatic or give rise to left upper quadrant and left shoulder tip pain. Contrast-enhanced CT will show the characteristic perfusion defect in the enlarged spleen (***Figure 70.9***). Treatment is conservative and splenectomy should be considered only when a septic infarct causes an abscess.

Splenic rupture due to trauma

The spleen is the most commonly injured intra-abdominal organ followed by the liver. Splenic rupture should be considered in any case of blunt abdominal trauma, particularly when

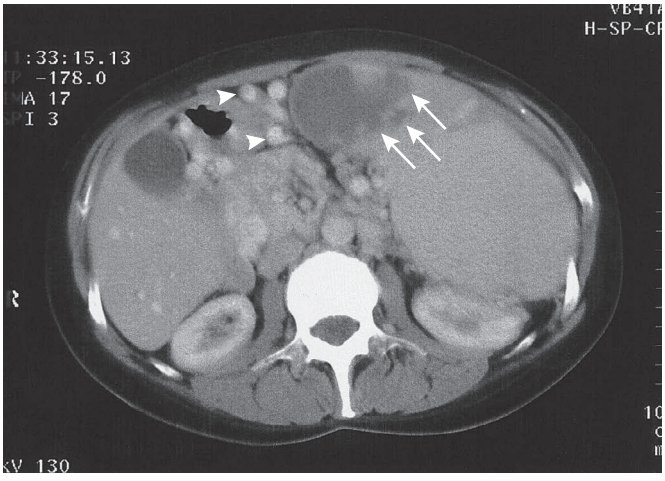

Figure 70.9 Computed tomography scan showing a splenic infarct (arrows) in a patient with splenomegaly and hypersplenism secondary to portal hypertension and portal vein thrombosis. Varices are evident at the hilus and at the greater curvature of the stomach (arrowheads).

TABLE 70.1 Criteria for grading of splenic injury based on computed tomography.

Grade 1	Subcapsular haematoma <10% of surface area Parenchymal laceration <1 cm depth Capsular tear
Grade 2	Subcapsular haematoma 10–50% of surface area; intraparenchymal haematoma <5 cm Parenchymal laceration 1–3 cm
Grade 3	Subcapsular haematoma >50% surface area; ruptured subcapsular or intraparenchymal haematoma ≥5 cm Parenchymal laceration >3 cm depth
Grade 4	Any injury in the presence of a splenic vascular injury or active bleeding confined within the splenic capsule Parenchymal laceration involving segmental or hilar vessels producing >25% devascularisation
Grade 5	Any injury in the presence of splenic vascular injury[a] with active bleeding extending beyond the spleen into the peritoneum – shattered spleen

[a]Vascular injury is defined as a pseudoaneurysm or arteriovenous fistula and appears as a focal collection of vascular contrast that decreases in attenuation with delayed imaging. Active bleeding from a vascular injury presents as vascular contrast, focal or diffuse, that increases in size or attenuation in the delayed phase.

the injury occurs to the left upper quadrant of the abdomen. Iatrogenic injury to the spleen remains a frequent complication of any surgical procedure, particularly those in the left upper quadrant when adhesions are present.

Based upon the extent of injury, spleen rupture is classified into five grades on the basis of CT, which is considered to be the most important investigation for assessment of abdominal trauma in a haemodynamically stable patient (***Table 70.1***). Vigorous resuscitation remains the key to management of blunt trauma. Splenectomy should be performed for severe grades of injury where control of bleeding takes precedence over measures to salvage the spleen. Splenic angiography with embolisation of actively bleeding vessels may obviate the need for splenectomy but should not delay laparotomy in a haemodynamically unstable patient.

Rupture of a malarial spleen

In tropical countries, rupture of a spleen enlarged as a result of malaria is not uncommon (see ***Tropical splenomegaly***). Delayed presentation following a 'trivial' injury is not infrequent. In such patients, radiological embolisation may be performed if available, and splenectomy should be considered before a perisplenic haematoma ruptures, a complication that is associated with a worse prognosis.

Surgery in such patients is challenging and early ligation of the splenic vessels along the superior border of the pancreatic body should be considered before disturbing the haematoma.

SPLENOMEGALY AND HYPERSPLENISM

Splenomegaly is a common feature of many disease processes, although the spleen has to enlarge threefold before it is palpable (***Table 70.2***). It should be borne in mind that many conditions affecting the spleen, such as idiopathic thrombocytopenic purpura (ITP), may be associated with enlargement but the spleen is seldom palpable. Few conditions that cause splenomegaly will require splenectomy as part of treatment.

Hypersplenism is an indefinite clinical syndrome that is characterised by splenic enlargement, any combination of anaemia, leukopenia or thrombocytopenia, compensatory bone marrow hyperplasia and improvement after splenectomy. Careful clinical judgement is required to balance the long- and short-term risks of splenectomy against continued conservative management.

Splenic abscess

Splenic abscess may arise from an infected splenic embolus or in association with typhoid and paratyphoid fever, osteomyelitis, otitis media and puerperal sepsis. In general surgical practice, it may be associated with pancreatic necrosis or other intra-abdominal infection (***Figure 70.10***). An abscess may rupture and form a left subphrenic abscess or result in diffuse peritonitis. Treatment involves that of the underlying cause; percutaneous drainage of the splenic abscess under radiological guidance is normally required, with splenectomy being reserved when interventional radiology is not available.

Tuberculosis

The diagnosis of tuberculosis should be considered in young adults with splenomegaly presenting with asthenia, loss of weight and fever. Tuberculosis of the spleen may produce portal hypertension or, rarely, cold abscess. CT shows small low-attenuation areas with central enhancement in the acute stage and MRI shows hypointense lesions (***Figure 70.11***). Multidrug chemotherapy with four drugs in the intensive phase of 2 months followed by two drugs in the maintenance

TABLE 70.2 Causes of splenic enlargement.

Infective	Bacterial	Typhoid and paratyphoid
		Typhus
		Tuberculosis
		Psittacosis
		Septicaemia
		Splenic abscess
	Spirochaetal	Weil's disease
		Syphilis
	Viral	Infectious mononucleosis
		HIV-related thrombocytopenia
	Protozoal and parasitic	Malaria
		Schistosomiasis
		Trypanosomiasis
		Kala-azar
		Hydatid cyst
		Tropical splenomegaly
Blood disease	Acute leukaemia	Idiopathic thrombocytopenic purpura
	Chronic leukaemia	Hereditary spherocytosis
	Pernicious anaemia	Autoimmune haemolytic anaemia
	Polycythaemia vera	Thalassaemia
	Erythroblastosis fetalis	Sickle cell disease
Metabolic	Rickets	
	Amyloid	
	Porphyria	
	Gaucher's disease	
Circulatory	Infarct	
	Portal hypertension	
	Segmental portal hypertension	(Pancreatic carcinoma, splenic vein thrombosis)
Collagen disease	Still's disease	
	Felty's syndrome	
Non-parasitic cysts	Congenital	
	Acquired	
Neoplastic	Angioma	
	Primary fibrosarcoma	
	Hodgkin's lymphoma	
	Other lymphomas	
	Myelofibrosis	

HIV, human immunodeficiency virus.

Adolph Weil, 1848–1916, physician, Dorpat (now Tartu), Estonia, described leptospirosis icterohaemorrhagica in 1886.
Philippe Charles Ernest Gaucher, 1854–1918, dermatologist, Paris, France.
Sir George Frederic Still, 1868–1941, Professor of Diseases of Children, King's College Hospital, London, UK, described chronic articular rheumatism in children in 1896.
Augustus Roy Felty, 1895–1964, physician, Hartford, CT, USA, described the combination of arthritis, splenomegaly and leukopenia in 1924 while still a medical student at Johns Hopkins School of Medicine, Baltimore, MD, USA.
Thomas Hodgkin, 1798–1870, lecturer in morbid anatomy and curator of the museum, Guy's Hospital, London, UK, described lymphadenoma in 1836.

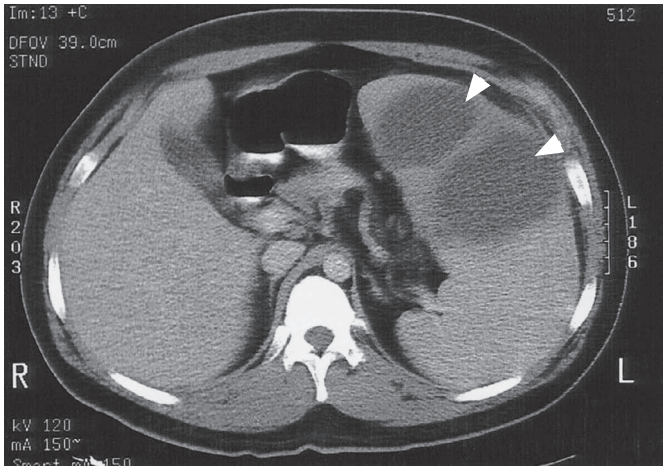

Figure 70.10 Computed tomography scan showing a multiloculated abscess (arrowheads) in the enlarged spleen. This was managed successfully by percutaneous drainage under ultrasound guidance.

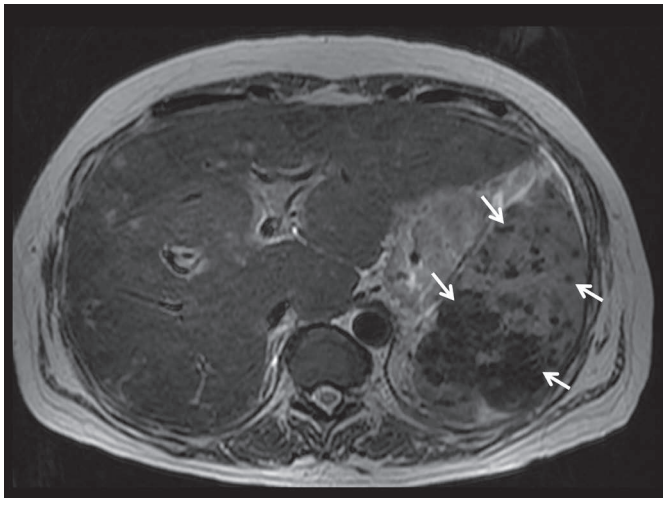

Figure 70.11 T2-weighted axial magnetic resonance image showing multiple hypointense lesions (arrows) of varying sizes in the spleen, suggestive of tuberculosis (courtesy of Dr Ruchi Rastogi, New Delhi, India).

phase for a total duration of 12–18 months is preferred for treatment of extrapulmonary tuberculosis. Splenectomy is not normally required and is made difficult by inflammatory adhesions. Typical epithelioid cell granulomas are seen in the histopathology of the spleen only if splenectomy had to be performed (***Figure 70.12***).

Tropical splenomegaly

Massive splenic enlargement frequently occurs in the tropics from malaria, kala-azar and schistosomiasis. Occasionally, splenomegaly cannot be fully attributed to these diseases and may result from occult infection or be related to malnutrition. Massive splenomegaly may require removal because of anaemia, hypersplenism, local symptoms or the threat of rupture. Lifelong antimalarial therapy is indicated in endemic areas.

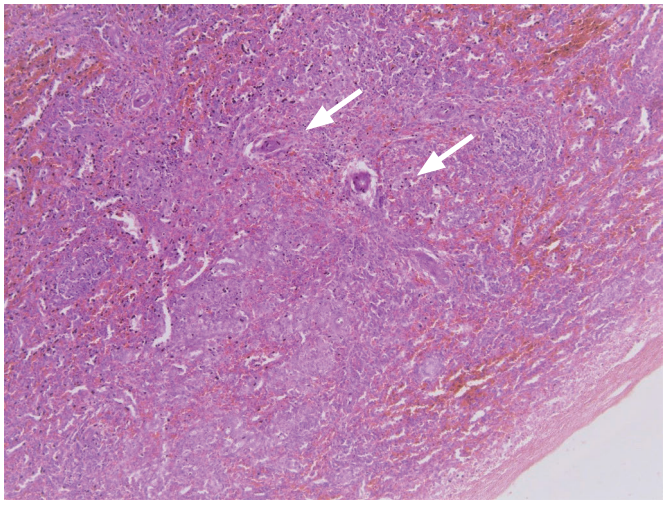

Figure 70.12 Splenic parenchyma showing epithelioid cell granulomas (arrows) in a human immunodeficiency virus-positive patient with disseminated cryptococcosis who presented with spontaneous splenic rupture necessitating splenectomy; haematoxylin and eosin; ×200 (courtesy of Dr Nita Khurana, New Delhi, India).

Schistosomiasis

This condition is prevalent in Africa, Asia and South America. It is caused by infection with *Schistosoma mansoni* in 75% of cases and by *Schistosoma haematobium* in the remainder. Splenic enlargement may result from portal hypertension associated with hepatic fibrosis, but can also result from hyperplasia induced by the phagocytosis of disintegrated worms, ova and toxin. Splenomegaly can occur at any age. The diagnosis is based on examination of the urine and faeces for ova, abnormal liver function tests and the presence of hypochromic anaemia.

Successful medical treatment does not result in the regression of splenomegaly. Removal of a painful spleen may be indicated or as part of a devascularisation procedure in patients with associated portal hypertension.

Leukaemia

Leukaemia should be considered in the differential diagnosis of splenomegaly. The diagnosis is made by examining a blood or bone marrow film. Splenectomy is reserved for hypersplenism that occurs during the chronic phase of chronic granulocytic leukaemia.

Idiopathic thrombocytopenic purpura

ITP, also known as immune and autoimmune thrombocytopenic purpura, results from antibodies to specific platelet membrane glycoproteins (antiplatelet IgG autoantibodies) that result in isolated thrombocytopenia in the presence of normal bone marrow and the absence of other causes of thrombocytopenia. Two distinct clinical types are evident: an

Sir Patrick Manson, 1844–1922, practised in Formosa (now Taiwan) and Hong Kong before becoming physician to the Dreadnought Hospital, Greenwich, London, UK. He is regarded as 'the father of tropical medicine'.

acute condition in children and a chronic condition in adults. Acute ITP often follows an acute infection and usually resolves spontaneously. Chronic ITP persists longer than 6 months without a specific cause being identified.

Clinical features

The adult form normally affects females between the ages of 15 and 50 years, although it can be associated with other conditions, including systemic lupus erythematosus, chronic lymphatic leukaemia and Hodgkin's disease. The childhood form is distributed equally between males and females and commonly presents before the age of 5 years.

Purpuric patches (ecchymoses) occur on the skin and mucous membranes. Following trauma or pressure, examination often reveals numbers of petechial haemorrhages in the skin. There is a tendency to spontaneous bleeding from mucous membranes (e.g. epistaxis); menorrhagia in women and prolonged bleeding of minor wounds are common. Haemorrhage from the urinary and gastrointestinal tracts and haemarthrosis are rare. Although intracranial haemorrhage is also uncommon, it is the most frequent cause of death. The diagnosis is indicated by the presence of cutaneous ecchymoses and a positive tourniquet test. The spleen is palpable in fewer than 10% of patients. The presence of gross splenic enlargement should raise suspicion of an alternative diagnosis.

Investigations

Coagulation studies are normal and a bleeding time is not helpful in diagnosis. Platelet count in the peripheral blood film is reduced (usually $<60 \times 10^9$/L). Bone marrow aspiration reveals a plentiful supply of platelet-producing megakaryocytes.

Treatment

The course of the disease differs in children and adults. The disease usually regresses spontaneously in paediatric cases. Short courses of corticosteroids in both adults and children are usually followed by recovery. Steroid therapy should not be prolonged.

Splenectomy is usually recommended for refractory or relapsing ITP. Up to two-thirds of patients will be cured by surgical intervention and 15% will be improved, but no benefit will be derived in the remainder. The response to steroids predicts a good response to splenectomy if the disease relapses.

Laparoscopic splenectomy is rapidly becoming the mainstay of treatment since the size of the spleen is usually normal or slightly enlarged and the spleen is not friable. It is important to identify and remove splenunculi as they have the potential to enlarge with time and lead to recurrence of symptoms.

In the acute setting, fresh blood transfusion or transfusion with platelet concentrates before operation may be necessary, although these are generally withheld until the splenic vessels have been controlled.

Haemolytic anaemias

There are four causes of haemolytic anaemia that are generally amenable to splenectomy.

Hereditary spherocytosis

Hereditary spherocytosis is an autosomal dominant hereditary disorder characterised by the presence of spherocytic red cells, caused by various molecular defects in the genes that code for alpha- and beta-spectrin, ankyrin, band 3 protein, protein 4.2 and other erythrocyte membrane proteins. These proteins are necessary to maintain the normal biconcave shape of the erythrocyte.

Spherocytosis arises essentially from an increase in permeability of the red cell membranes to sodium. As this ion leaks into the cell, the osmotic pressure rises, resulting in swelling and increased fragility of the spherocyte. As the sodium pump has to work harder to rid the cells of sodium, there is greater loss of membrane phospholipid, resulting in an increased fragility of the membrane, and the energy and oxygen requirements increase. A large number of red cells are destroyed in the spleen, where there is a relative deficiency of both glucose and oxygen.

The clinical presentation is generally in childhood but may be delayed until later life. Mild intermittent jaundice is associated with mild anaemia, splenomegaly and gallstones. Circulating bilirubin is not conjugated with glucuronic acid and is not therefore excreted in the urine as it is bound to albumin. Excretion of the resulting bilirubin complex by the liver favours formation of pigment gallstones. Once the disease manifests itself, spontaneous remissions are uncommon; the patient is often pale and jaundiced at presentation and, in established cases, lassitude and undue fatigue are present.

In some families, the disease is characterised by a severe crisis of red blood cell destruction, during which the erythrocyte count may fall from 4.5×10^6/mL to 1.5×10^6/mL within 1 week. Such crises are characterised by the onset of pyrexia, abdominal pain, nausea, vomiting and extreme pallor, followed by increasing jaundice. These episodes may be precipitated by acute infection. Any child with gallstone disease should be investigated for hereditary spherocytosis and a family history sought.

Examination reveals splenomegaly and the liver may also be palpable. Chronic leg ulcers may arise in adults.

Haematological investigations include the fragility test. Erythrocytes begin to haemolyse in 0.47% saline solution but, in this condition, haemolysis may occur in 0.6% or even stronger solutions. Immature red blood cells (reticulocytes), which differ from adult cells by possessing a reticulum, are discharged into the circulation by the bone marrow to compensate for the loss of erythrocytes by haemolysis.

Faecal urobilinogen is increased as this route excretes most of the urobilinogen.

Radioactive chromium (^{51}Cr) labelling of the patient's own red cells will demonstrate the severity of red cell destruction. Daily scanning over the spleen will show the degree of red cell sequestration by the spleen. The presence of high levels of splenic radioactivity generally predicts a good response to splenectomy.

All patients with hereditary spherocytosis should be treated by splenectomy but, in juvenile cases, this is generally delayed until 6 years of age to minimise the risk of postsplenectomy

infection, but before gallstones have had time to form. Ultrasonography should be performed preoperatively to determine the presence of gallstones.

Acquired autoimmune haemolytic anaemia

This condition is divided into immune- and non-immune-mediated forms. It may arise following exposure to agents such as chemicals, infection or drugs, e.g. alpha-methyldopa, or be associated with another disease (e.g. systemic lupus erythematosus). In most instances, the cause is unknown, and red cell survival is reduced because of an immune reaction triggered by immunoglobulin or complement on the red cell surface. The condition is more common in women after the age of 50 years. The spleen is enlarged in about half the patients and pigment gallstones are present in about 20%.

Anaemia is invariably present and may be associated with spherocytosis because of red cell membrane damage. In the immune type, antibody, which coats the red cells, can be detected by agglutination when anti-human globulin is added to a suspension of the patient's erythrocytes (Coombs' test positive). The disease runs an acute self-limiting course and no treatment is necessary. Splenectomy should, however, be considered if corticosteroids are ineffective, when the patient is developing complications from long-term steroid treatment or if corticosteroids are contraindicated; 80% of patients respond to splenectomy.

Thalassaemia (synonyms: Cooley's anaemia, Mediterranean anaemia)

This condition results from a defect in haemoglobin peptide chain synthesis and is transmitted most commonly as a recessive trait. The disease is really a group of related diseases, alpha, beta and gamma, depending upon which haemoglobin peptide chain rate of synthesis is reduced. Most patients have beta-thalassaemia, in which a reduction in the rate of beta-chain synthesis results in a decrease in haemoglobin A. Intracellular precipitates (Heinz bodies) contribute to premature red cell destruction.

Graduations of the disease range from heterozygous thalassaemia minor to homozygous thalassaemia major, which is associated with chronic anaemia, jaundice and splenomegaly. Patients with homozygous thalassaemia major frequently develop clinical signs in the first year of life, and these include retarded growth, enlarged head with slanting eyes and depressed nose, leg ulcers, jaundice and abdominal distension secondary to splenomegaly.

Red cells are small, thin and misshapen and have a characteristic resistance to osmotic lysis. In the more severe forms, nucleated red cells and other immature blood cells are seen. The diagnosis is confirmed by haemoglobin electrophoresis.

Blood transfusion may be required to correct profound anaemia, but the patient may become transfusion dependent because of hypersplenism. Splenectomy is therefore of benefit in patients who require frequent blood transfusion or if haemolytic antibodies have developed.

Sickle cell disease

Sickle cell disease is a hereditary, autosomal recessive haemolytic anaemia occurring mainly among those of African origin, in whom the normal haemoglobin A is replaced by haemoglobin S (HbS). The HbS molecule crystallises when blood oxygen tension is reduced, thus distorting and elongating the red cell. The resulting increased blood viscosity may obstruct the flow of blood in the spleen. Splenic microinfarcts are therefore common.

The sickle cell trait can be detected in 9% of those of African origin, but most are asymptomatic; sickle cell disease occurs in about 1% of Africans. Depending upon the vessels affected by vascular occlusion, patients may complain of bone or joint pain, priapism, neurological abnormalities, skin ulcers or abdominal pain due to visceral blood stasis. The diagnosis is made by finding characteristic sickle-shaped cells on blood film, although this investigation has largely been replaced by haemoglobin electrophoresis.

Hypoxia that provokes a sickling crisis should be avoided and is particularly relevant in patients undergoing general anaesthesia. Adequate hydration and partial exchange transfusion may help in a crisis. Splenectomy is of benefit in a few patients in whom excessive splenic sequestration of red cells aggravates the anaemia. Chronic hypersplenism usually occurs in late childhood or adolescence, although *Streptococcus pneumoniae* infection may precipitate an acute form in the first 5 years of life.

Porphyria

Porphyria is a hereditary error of haemoglobin catabolism in which porphyrinuria occurs. The urine may be orange and develops a port-wine colour after a few hours of exposure to the air. Splenectomy has little role to play in the management.

Gaucher's disease

This lipid storage disease is characterised by storage of glucocerebroside in the reticuloendothelial system and in the spleen. Enormous splenic enlargement may be associated with yellowish brown discoloration of the skin on the hands and face, anaemia and conjunctival thickening (pinguecula). Slavonic and Jewish races are more prone to the disease, and the detection of Gaucher cells in the bone marrow confirms the diagnosis. Splenectomy is indicated only for severe symptoms related to the splenomegaly.

Hypersplenism due to portal hypertension

Splenomegaly is an invariable feature of portal hypertension (***Figure 70.13***) and results in the thrombocytopenia and granulocytopenia observed in these patients. These may be improved if the portal hypertension is relieved by shunt surgery or liver transplantation. Splenectomy would normally be required only in those patients whose segmental portal hypertension has

Robin Royston Amos Coombs, 1921–2006, Quick Professor of Biology, University of Cambridge, Cambridge, UK, described this test in 1945.
Thomas Benton Cooley, 1871–1945, Professor of Pediatrics, Wayne University, Detroit, MI, USA, described this type of anaemia in 1927.

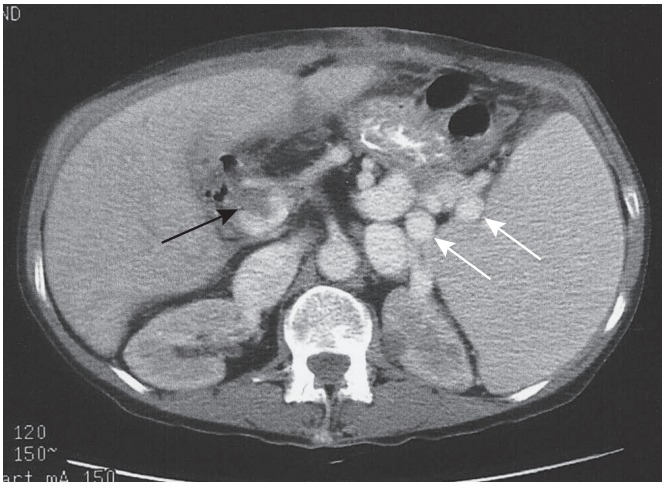

Figure 70.13 Computed tomography scan showing an enlarged spleen in a patient with portal hypertension secondary to portal vein thrombosis. Clot is evident within the lumen of the portal vein (black arrow) and large vessels of portosystemic shunts (white arrows) are present at the splenic hilus.

resulted in symptomatic oesophagogastric varices either as a standalone procedure in cases with massive splenomegaly due to extrahepatic portal vein obstruction or in combination with proximal lienorenal shunt (see ***Chapter 69***).

Felty's syndrome

Patients with rheumatoid arthritis may develop leukopenia. This is referred to as Felty's syndrome if it is extreme and associated with splenomegaly. Splenectomy produces only a transient improvement in the blood picture, but rheumatoid arthritis may respond to steroid therapy to which it had previously become resistant.

NEOPLASMS

Haemangioma is the most common benign tumour of the spleen. It may rarely develop into a haemangiosarcoma. The spleen is rarely the site of metastatic disease. Lymphoma is the most common cause of neoplastic enlargement and splenectomy may play a part in its management.

Splenectomy may be required to achieve a diagnosis in the absence of palpable lymph nodes or to relieve the symptoms of gross splenomegaly. However, the need for staging laparotomy or laparoscopy has largely receded with the advent of CT and guided biopsy. Its use has been restricted to those patients in whom a definite histological diagnosis of intra-abdominal disease will affect management. In the absence of obvious liver or intra-abdominal nodal disease, splenectomy is an integral part of the staging procedure to exclude splenic involvement, which would alter the method of treatment.

Myelofibrosis results from an abnormal proliferation of mesenchymal elements in the bone marrow, spleen, liver and lymph nodes. Most patients present over the age of 50 years, and the spleen may produce pain owing to its gross enlargement (***Figure 70.14***) or to splenic infarcts. Splenectomy reduces the need for transfusion and may relieve the discomfort resulting from the splenomegaly.

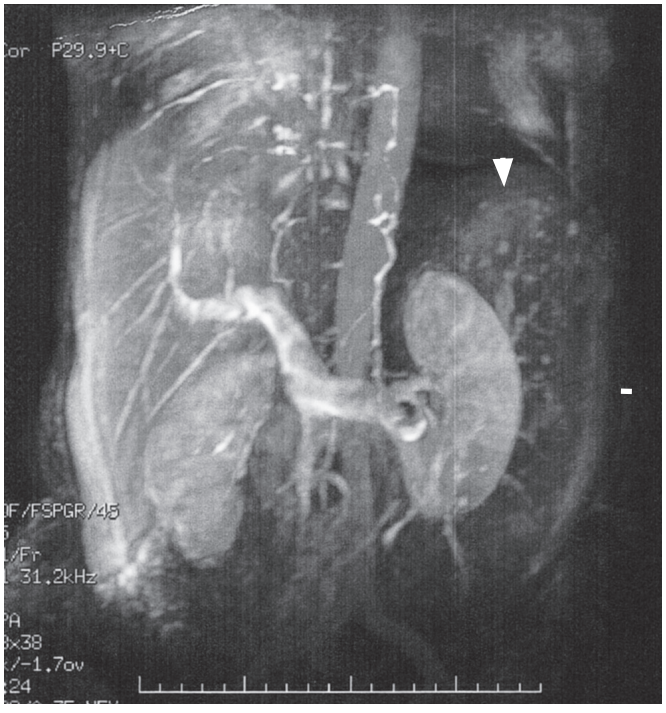

Figure 70.14 Magnetic resonance imaging scan showing massive hepatosplenomegaly secondary to myelofibrosis. Note the prominent portal system and the left kidney, which is superimposed over the grossly enlarged spleen (arrowheads).

SPLENECTOMY

The common indications for splenectomy are:

- trauma resulting from an accident or iatrogenic during a surgical procedure; for example, during mobilisation of the oesophagus, stomach, distal pancreas or splenic flexure of the colon;
- removal en bloc with the stomach as part of a radical gastrectomy or with the pancreas as part of a distal or total pancreatectomy;
- to treat anaemia or thrombocytopenia in spherocytosis, ITP or hypersplenism;
- in association with shunt or variceal surgery for portal hypertension.

Summary box 70.2

Indications for splenectomy

Trauma
- Accidental
- Iatrogenic

Oncological
- Part of *en bloc* resection
- Diagnostic
- Therapeutic

Haematological
- Spherocytosis
- Purpura (ITP)
- Hypersplenism

Portal hypertension
- Variceal surgery

Preoperative preparation

In the presence of a bleeding tendency, transfusion of blood, fresh-frozen plasma, cryoprecipitate or platelets may be required. Coagulation profiles should be as near normal as possible at operation, and platelets should be available for patients with thrombocytopenia during operation and in the early postoperative period.

Antibiotic prophylaxis appropriate to the operative procedure should be given, and consideration should be given to the risk of postsplenectomy sepsis (see ***Postoperative complications***).

Technique of open splenectomy

Most surgeons use a midline or transverse left subcostal incision for open splenectomy with the patient in the supine position. Rarely, a thoracoabdominal incision may be necessary for a massive spleen that is adherent to the diaphragm. Passage of a nasogastric tube following induction of the anaesthetic enables the stomach to be emptied.

In elective splenectomy, the gastrosplenic ligament is opened and the short gastric vessels are divided. The splenic vessels at the superior border of the pancreas are suture ligated. Division of the posterior leaf of the lienorenal ligament with long curved scissors on the posterior surface of the spleen helps to rotate and deliver the spleen medially into the laparotomy wound along with the tail and body of the pancreas. The posterior surface of the spleen is exposed and the spleen rotated medially along with the tail and body of the pancreas (***Figure 70.15***). The pancreas is separated from the hilar vessels, which are normally doubly ligated separately and divided. Accessory splenic tissue in the splenic hilum or omentum should be excluded by a careful search at operation. There is no need to drain the wound.

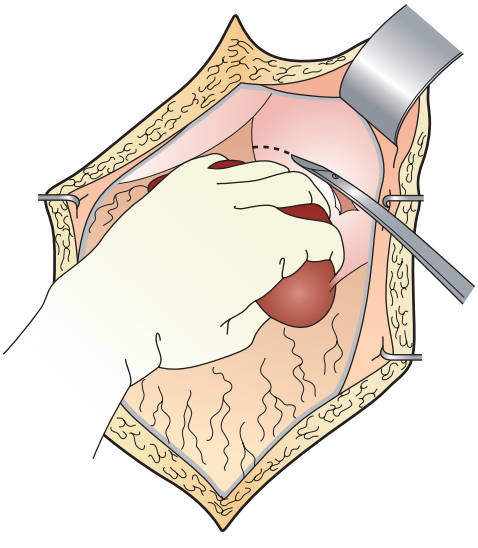

Figure 70.15 Diagrammatic view of the approach to mobilise the spleen at open surgery with division of the peritoneal fold of the lienorenal ligament posteriorly using Metzenbaum scissors, enabling delivery of the spleen into the laparotomy wound.

The segmental vasculature of the spleen does make it possible to undertake limited resection of the parenchyma. Haemostasis can be achieved by ligation of, or application of metal clips to, intrasplenic vessels and by careful application of topical haemostatic agents. Conservative splenic surgery is therefore possible in some cases of splenic trauma and other pathology such as splenic cysts.

Technique of laparoscopic splenectomy

The patient is placed on the right side with the space between the left ilium and costal margin exposed. Placement of access ports is often determined by the size of the patient and the spleen. Insufflation of the abdomen can be performed once access is obtained through an incision 1 cm from the costal margin at the left midclavicular line. A further trocar is inserted close to the costal margin below the xiphoid. A 12-mm trocar is inserted at a similar distance from the costal margin at the posterior axillary line. The splenocolic ligament is divided to give access to the lower splenic pole. The spleen is separated from the kidney and diaphragm before the gap between the splenic hilum and the tail of the pancreas is enlarged. The spleen is elevated to expose the splenic hilum, which is secured and divided with an endoscopic vascular stapler (***Figure 70.16***). Two or three applications of the instrument may be required to secure the hilum and the short gastric vessels. Any remaining attachments to the diaphragm are divided before a self-retaining opening bag is introduced through the incision of the open laparoscopy, after removal of the 12-mm port.

Postoperative complications

Immediate complications specific to splenectomy include haemorrhage resulting from a slipped ligature. Left basal

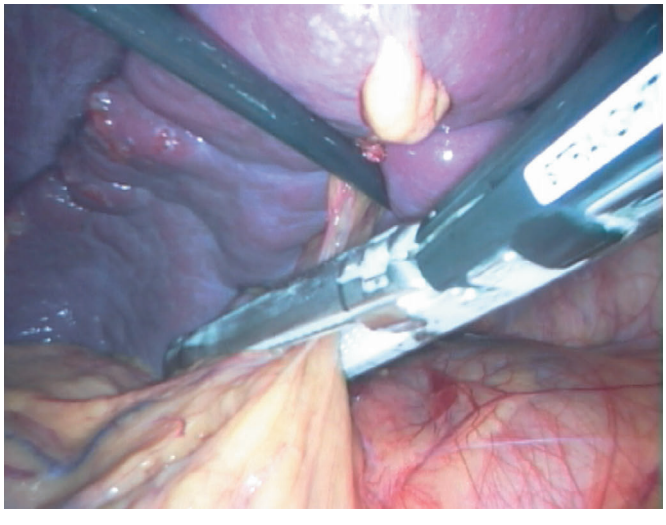

Figure 70.16 Photograph showing a stapling device across the splenic hilus for division of the splenic vessels during laparoscopic splenectomy.

Myron Firth Metzenbaum, 1876-1944, surgeon, Cleveland, OH, USA.

atelectasis is common and a pleural effusion may be present. Adjacent structures at risk during the procedure include the stomach and pancreas. A fistula may result from damage to the greater curvature of the stomach during ligation of the short gastric vessels. Damage to the tail of the pancreas during ligation of the splenic vessels at the hilum may result in pancreatitis, a localised abscess or a pancreatic fistula. Haematemesis from gastric mucosal damage and gastric dilatation are uncommon.

Postoperative thrombocytosis may arise and, if the blood platelet count exceeds 1×10^6/mL, prophylactic aspirin is recommended. Long-term surveillance programmes have emphasised an increased risk of deep vein thrombosis and pulmonary embolism. The relative risk and benefit of thromboprophylaxis in this setting has not been assessed adequately.

Postsplenectomy septicaemia may result from *S. pneumoniae, Neisseria meningitides, Haemophilus influenzae* or *Escherichia coli*. Long-term surveillance programmes have suggested that the risk of pneumonia, meningitis and major sepsis following splenectomy is increased threefold. However, the risk is greater in the young patient, in splenectomised patients treated with chemoradiotherapy and in patients who have undergone splenectomy for thalassaemia, sickle cell disease and autoimmune anaemia or thrombocytopenia.

Opportunist postsplenectomy infection (OPSI) is a major concern. Published guidelines emphasise that most infections after splenectomy could be avoided through measures that include offering patients appropriate and timely immunisation, antibiotic prophylaxis, education and prompt treatment of infection. The benefit of prophylactic antibiotics in this setting remains controversial. It is thought that children who have undergone splenectomy before the age of 5 years should be treated with a daily dose of penicillin until the age of 10 years. Prophylaxis in older children should be continued at least until the age of 16 years, but its use is less well defined in adults. Furthermore, compliance is problematic in the long term but, as the risk of overwhelming sepsis is greatest within the first 2–3 years after splenectomy, it seems reasonable to give prophylaxis during this time. However, all patients with compromised immune function should receive prophylaxis. Satisfactory oral prophylaxis can be obtained with penicillin, erythromycin, amoxicillin or co-amoxiclav. Suspected infection can be treated intravenously with these same antibiotics and cefotaxime or ceftriaxone, or chloramphenicol in patients allergic to penicillin and cephalosporins.

If elective splenectomy is planned, consideration should be given to vaccinating against pneumococcus, meningococcus C (both repeated every 5 years) and *H. influenzae* type b (Hib) (repeated every 10 years). The last two vaccines are commonly delivered as a combined preparation. Yearly influenza vaccination has been recommended, as there is some evidence that it may reduce the risk of secondary bacterial infection. Such vaccinations should be administered at least 2 weeks before elective surgery or as soon as possible after recovery from surgery but before discharge from hospital. Pneumococcal vaccination is recommended in those patients aged over 2 years. Hib vaccination is recommended irrespective of age. Asplenic patients should carry a medical alert and an up-to-date vaccination card. They require specific advice regarding travel and animal handling. OPSI due to *Capnocytophaga canimorsus* may result from dog, cat or other animal bites.

Vaccination can be given in the postoperative period following splenectomy for trauma, and the resulting antibody levels will be protective in the majority of cases. Antibody levels are, however, less than 50% of those achieved if vaccination is given in the presence of an intact spleen. Protection following vaccination is not always guaranteed.

Summary box 70.3

Splenectomy

- Remember preoperative immunisation
- Prophylactic antibiotics in children and immune compromised adults
- Opportunistic postsplenectomy infection is a real clinical danger
- Splenic conservation should be considered

FURTHER READING

Boyle S, White RH, Brunson A, Wun T. Splenectomy and the incidence of venous thromboembolism and sepsis in patients with immune thrombocytopenia. *Blood* 2013; **121**: 4782–90.

Di Sabatino A, Carsetti R, Corazza GR. Post splenectomy and hyposplenic states. *Lancet* 2011; **378**: 86–97.

Easow MM, Sharma A, Aravindakshan R. Splenectomy for people with thalassaemia major or intermedia. *Cochrane Database Syst Rev* 2014; Issue 6, Art. No. CDO10517.

Edgren G, Almqvist R, Hartman M, Utter GH. Splenectomy and the risk of sepsis: a population-based cohort study. *Ann Surg* 2014; **260**: 1081–7.

Glasgow RE, Mulvihill SJ. Laparoscopic splenectomy. *World J Surg* 1999; **23**: 384–8.

Kozar RA, Crandall M, Shanmuganathan K *et al.* Organ injury scaling 2018 update: spleen, liver, and kidney. *J Trauma Acute Care Surg* 2018; **85**(6): 1119–22.

Mourtzoukou EG, Mikhael J, Northridge K *et al.* Short-term and long-term failure of laparoscopic splenectomy in adult immune thrombocytopenic purpura patients: a systematic review. *Am J Hematol* 2009; **84**(11): 743–8.

Pappas G, Peppas G, Falagas ME. Vaccination of asplenic or hyposplenic adults. *Br J Surg* 2008; **95**(3): 273–80.

Sarin SK, Kumar A, Chawla YK *et al.* Noncirrhotic portal fibrosis/idiopathic portal hypertension: APASL recommendations for diagnosis and treatment. *Hepatol Int* 2007; **1**(3): 398–413.

Weatherall DJ. The hereditary anaemias. *Br Med J* 1997; **314**: 492–6.

Albert Ludwig Siegmund Neisser, 1855–1916, Director of the Dermatological Institute, Breslau, Germany (now Wrocław, Poland).
Theodor Escherich, 1857–1911, Professor of Paediatrics, Vienna, Austria.